

Stellate Ganglion Block for Anosmia and Dysgeusia Due to Long COVID

Gaurav Chauhan¹, Aman Upadhyay², Suchit Khanduja³, Trent Emerick⁴

Review began 08/01/2022

Review ended 08/05/2022

Published 08/08/2022

© Copyright 2022

Chauhan et al. This is an open access article distributed under the terms of the Creative Commons Attribution License CC-BY 4.0., which permits unrestricted use, distribution, and reproduction in any medium, provided the original author and source are credited.

1. Anesthesiology and Perioperative Medicine, University of Pittsburgh Medical Center Presbyterian, Pittsburgh, USA
2. Pain Management, Pain Clinic of Michigan, Rochester Hills, USA 3. Anesthesiology, Beaumont Hospital, Southfield, USA 4. Pain Medicine, University of Pittsburgh Medical Center, Pittsburgh, USA

Corresponding author: Gaurav Chauhan, chauhang@upmc.edu

Abstract

Anosmia and parosmia refer to the loss or dysfunction of smell, respectively. Dysgeusia refers to taste disturbance. The coronavirus disease 2019 (COVID-19) pandemic and the subsequent phenomenon of Long COVID syndrome have been associated with an increased incidence of anosmia and dysgeusia. Smell and taste disturbances associated with COVID-19 are usually self-limiting but can persist for longer periods in some cases. Imbalances of the autonomic nervous system, especially dysregulation of the sympathetic system, are implicated in the persistence of anosmia and dysgeusia post-COVID-19 infection. Stellate ganglion block (SGB) can diminish the increased sympathetic activity and potentially resolve anosmia and dysgeusia occurring due to Long COVID. The authors report the successful resolution of persistent anosmia and dysgeusia due to Long COVID in a female patient after she underwent SGB.

Categories: Pain Management, Infectious Disease, Anatomy

Keywords: dysautonomia, dysgeusia, anosmia, long-covid, covid-19

Introduction

Anosmia and parosmia are defined as the loss or dysfunction of smell, respectively. Dysgeusia refers to taste disturbance. There is an increased prevalence of anosmia/parosmia in patients who have clinically recovered from coronavirus disease 2019 (COVID-19) infection. According to the current literature, the incidence rate of olfactory dysfunction in COVID-19 patients varies from 33.9 to 68%, with a female predominance [1]. Anosmia and dysgeusia could be self-limiting over a two- or three-week period post-COVID-19 infection but can persist for longer. Despite a high recovery rate, multiple studies have reported that up to 7% of the patients still experience smell and taste disturbances more than 12 months after the onset [2,3]. Anosmia and dysgeusia might coexist with other symptoms such as fatigue, orthostatic hypotension, shortness of breath, insomnia, anxiety, and depression. These constellations of symptoms may persist chronically and are termed "Long COVID", or formally, post-acute sequelae of SARS-CoV-2 (PASC) infection [3]. The incidence of PASC is 30% in symptomatic and 5% in asymptomatic patients with COVID-19 infection [4]. Compared to influenza, COVID-19 is reported to be associated with a higher prevalence of anosmia (53% vs. 17%) [5]. PASC patients with or without hospitalization have often reported anosmia and dysgeusia as one of the predominant and persisting symptoms [4].

Smell and taste disturbances associated with COVID-19 infection have generated a lot of interesting etiological hypotheses. One such theory implicates autonomic dysregulation or dysautonomia as the underlying mechanism behind anosmia [6]. In the case of Long COVID, dysautonomia could be induced by the autonomic nervous system's (ANS) response or maladaptation to pro-inflammatory cytokines leading to excessive sympathetic nervous system activity [4,6,7]. Sympathetic innervation of the head and neck consists of the cervical and upper thoracic sympathetic chain [8]. It is postulated that unrestrained cervical sympathetic activity in the head and neck region can be blocked by injecting local anesthetics in the stellate ganglion, restoring the homeostasis of the regional ANS [9]. The stellate ganglion block (SGB) has been used clinically for medical conditions associated with increased sympathetic nervous system activity [10-12]. In this report, the authors discuss the resolution of persistent anosmia after performing SGB in a patient who had completely recovered from COVID-19 infection, implicating dysautonomia in the pathophysiology of PASC.

This article was previously posted to the QEIOS preprint server on June 11, 2022.

Case Presentation

A 48-year-old female patient, who consented to the publishing of this case report, presented to our clinic four months after recovering from a COVID-19 infection. The patient did not have any significant comorbidities. She reported that she had developed fevers ranging from 99 to 102 °F, non-productive cough, and nasal congestion. The reverse transcriptase polymerase chain reaction test (RT-PCR) performed on the patient's nasal swab, at a drive-through laboratory, had revealed a positive COVID-19 infection.

How to cite this article

Chauhan G, Upadhyay A, Khanduja S, et al. (August 08, 2022) Stellate Ganglion Block for Anosmia and Dysgeusia Due to Long COVID. *Cureus* 14(8): e27779. DOI 10.7759/cureus.27779

The patient was placed on antiviral therapy (a combination of nirmatrelvir and ritonavir tablets known as Paxlovid) for five days, followed by a complete resolution of symptoms. She reported that she had first noticed the loss of smell and taste three to four days into the acute phase of COVID-19 and attributed it to nasal congestion and high fevers. The patient also reported fatigue, light-headedness, and loss of smell and taste. She reported that all her symptoms had resolved within one month, except for issues with taste and smell. She reported a complete loss of sense of smell and altered taste sensation to various types of foods. The patient further reported that she had tried various nasal decongestants and mucolytic agents. She frequently did nasal irrigation with saline. The patient had also failed olfactory threshold tests. No conductive loss of sense of smell was identified, such as nasal obstruction due to rhinosinusitis or allergic rhinitis. The patient also underwent gustatory tests with taste strips and was able to identify only salty and bitter tastes. At six months post-COVID-19 infection, she continued to have anosmia and difficulty tasting sweet and sour foods.

Anosmia and dysgeusia were affecting her quality of life, and she was getting annoyed due to a lack of therapeutic options. She had been finally referred to our clinic by her otolaryngologist for undergoing SGB. The patient was counseled that the authors would perform SGB based on anecdotal examples in the current literature. The patient underwent a right-sided SGB under ultrasonographic guidance, with 4 ml of 0.25% bupivacaine (Figure 1).

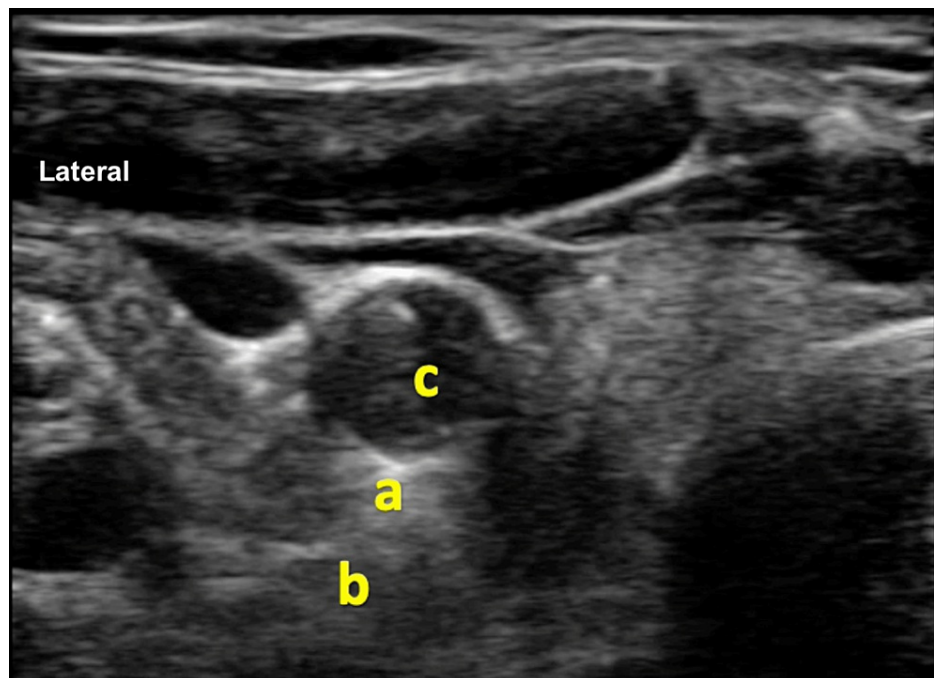


FIGURE 1: Ultrasonographic image of the right side of the neck depicting stellate ganglion

a: stellate ganglion above the longus colli muscle. Site for deposition of local anesthetic solution. b: longus colli muscle. c: right carotid artery

The patient reported a partial return of her sense of smell within 24 hours. She then underwent the left-sided SGB after 72 hours and reported a complete resolution of anosmia 24 hours after the second SGB. She reported that her altered taste sensation resolved a few days after the last block.

Discussion

Anosmia/parosmia as a part of COVID-19 infection could be due to neurological virulence and associated cytopathic effects [13,14]. Regarding patients reporting resolution of anosmia post-SGB, an argument could be made that they might have undergone structural recovery and only need to reset the tone of the ANS to experience functional recovery. Furthermore, a dramatic resolution of anosmia after SGB favors dysautonomia rather than cytopathic or structural damage due to COVID-19 as the underlying etiology.

Dysautonomia is also reported with other viral illnesses (hepatitis C, HIV, Epstein-Barr virus) and other pathologies such as alcoholism, diabetes, and Parkinson's. Dysautonomia is associated with fatigue, anosmia, heart rate variability, bowel and bladder dysfunction, and orthostatic hypotension [6]. Multiple theories have been proposed to explain the persistence of dysautonomia post-COVID-19 infection [15].

Current literature implicates the complex interaction between the angiotensin-converting enzyme 2 (ACE2) receptor and COVID-19 as the underlying mechanism behind dysautonomia and subsequent anosmia. ACE2 enzyme converts angiotensin II (Ang II) to angiotensin (1-7) [16]. Ang inhibits inflammation [17]. ACE2, expressed in membrane-bound and soluble forms, is the receptor for the spike portion of the SARS-CoV-2 virus. A link between ACE2 and the spike portion of SARS-CoV-2 facilitates the viral entry into the cells while inhibiting the activity of the ACE2 enzyme. A subsequent decrease in the activity of ACE2 potentiates inflammation by perpetuating the feed-forward loop mediated by the ATII molecule [18]. Furthermore, auto-antibodies, such as anti-interferon, anti-nuclear, and anti-phospholipids, are ubiquitously detected in patients with PASC. Antibodies to ACE2 enzyme can also perpetuate inflammation and dysautonomia by reducing the activity of both membrane-bound and soluble ACE2 [19-21]. ACE2-viral interaction theory also explains an increased incidence of anosmia in patients of European descent with an increased expression of ACE2 compared to Asians [22]. The expression of ACE2 also increases with age, explaining the less severe prognosis of COVID-19 infection in young adults and children [23]. The female gender, with overexpression of ACE2 as compared to males, has an increased propensity for olfactory issues due to COVID-19 infection [24].

Irrespective of etiology, sequelae of COVID-19 neurotropism and tissue injury entail chronic sympathetic hyperresponsiveness, vasomotor dysfunction, persistent chronic inflammation, and aberrant neuroplasticity manifesting clinically as dysautonomia. Impaired cerebral blood flow (CBF) is a common observation reported in subjects with dysautonomia [6,7,25]. Various reports have established that CBF impairment parallels dysautonomia's clinical severity in patients with PASC [26]. SGB improves CBF under normotensive conditions [27]. The increase in CBF leading to improved perfusion of cortical areas associated with the sense of smell or the peripheral receptors in the facial region might be responsible for the immediate resolution of anosmia seen with SGB. However, the exact mechanism behind the dramatic resolution of anosmia post-SGB is still unknown.

Conclusions

The mechanistic factors related to the dramatic improvement of anosmia due to SGB are still debatable; however, SGB may be an effective treatment option for patients with olfactory and taste issues associated with PASC. At this point, the evidence for using SGB to alleviate anosmia and dysgeusia associated with Long COVID is anecdotal and limited to a few case reports. Collaborative multi-institutional research might be required to gather more evidence to support using SGB as a treatment modality for anosmia and dysgeusia due to Long COVID.

Additional Information

Disclosures

Human subjects: Consent was obtained or waived by all participants in this study. **Conflicts of interest:** In compliance with the ICMJE uniform disclosure form, all authors declare the following: **Payment/services info:** All authors have declared that no financial support was received from any organization for the submitted work. **Financial relationships:** All authors have declared that they have no financial relationships at present or within the previous three years with any organizations that might have an interest in the submitted work. **Other relationships:** All authors have declared that there are no other relationships or activities that could appear to have influenced the submitted work.

References

- Meng X, Deng Y, Dai Z, Meng Z: COVID-19 and anosmia: a review based on up-to-date knowledge . *Am J Otolaryngol*. 2020, 41:102581. [10.1016/j.amjoto.2020.102581](https://doi.org/10.1016/j.amjoto.2020.102581)
- Karamali K, Elliott M, Hopkins C: COVID-19 related olfactory dysfunction. *Curr Opin Otolaryngol Head Neck Surg*. 2022, 30:19-25. [10.1097/MOO.0000000000000783](https://doi.org/10.1097/MOO.0000000000000783)
- Altundag A, Saatci O, Sanli DE, et al.: The temporal course of COVID-19 anosmia and relation to other clinical symptoms. *Eur Arch Otorhinolaryngol*. 2021, 278:1891-7. [10.1007/s00405-020-06496-5](https://doi.org/10.1007/s00405-020-06496-5)
- Vallée A: Dysautonomia and implications for anosmia in long COVID-19 disease . *J Clin Med*. 2021, 10:1-5. [10.3390/jcm10235514](https://doi.org/10.3390/jcm10235514)
- Zayet S, Kadiane-Oussou NJ, Lepiller Q, et al.: Clinical features of COVID-19 and influenza: a comparative study on Nord Franche-Comte cluster. *Microbes Infect*. 2020, 22:481-8. [10.1016/j.micinf.2020.05.016](https://doi.org/10.1016/j.micinf.2020.05.016)
- Eshak N, Abdelnabi M, Ball S, Elgwairi E, Creed K, Test V, Nugent K: Dysautonomia: an overlooked neurological manifestation in a critically ill COVID-19 patient. *Am J Med Sci*. 2020, 360:427-9. [10.1016/j.amjms.2020.07.022](https://doi.org/10.1016/j.amjms.2020.07.022)
- Stute NL, Stickford JL, Province VM, Augenreich MA, Ratchford SM, Stickford AS: COVID-19 is getting on our nerves: sympathetic neural activity and haemodynamics in young adults recovering from SARS-CoV-2. *J Physiol*. 2021, 599:4269-85. [10.1113/JP281888](https://doi.org/10.1113/JP281888)
- Kwon OJ, Pendekanti S, Fox JN, et al.: Morphological spectra of adult human stellate ganglia: implications for thoracic sympathetic denervation. *Anat Rec (Hoboken)*. 2018, 301:1244-50. [10.1002/ar.23797](https://doi.org/10.1002/ar.23797)
- Liu LD, Duricka DL: Stellate ganglion block reduces symptoms of Long COVID: a case series . *J Neuroimmunol*. 2022, 362:577784. [10.1016/j.jneuroim.2021.577784](https://doi.org/10.1016/j.jneuroim.2021.577784)
- Mulvaney SW, Lynch JH, Hickey MJ, Rahman-Rawlins T, Schroeder M, Kane S, Lipov E: Stellate ganglion block used to treat symptoms associated with combat-related post-traumatic stress disorder: a case series of

- 166 patients. *Mil Med.* 2014, 179:1133-40. [10.7205/MILMED-D-14-00151](https://doi.org/10.7205/MILMED-D-14-00151)
11. Tian Y, Wittwer ED, Kapa S, et al.: Effective use of percutaneous stellate ganglion blockade in patients with electrical storm. *Circ Arrhythm Electrophysiol.* 2019, 12:e007118. [10.1161/CIRCEP.118.007118](https://doi.org/10.1161/CIRCEP.118.007118)
 12. Rahimzadeh P, Imani F, Nafissi N, Ebrahimi B, Faiz SH: Comparison of the effects of stellate ganglion block and paroxetine on hot flashes and sleep disturbance in breast cancer survivors. *Cancer Manag Res.* 2018, 10:4831-7. [10.2147/CMAR.S173511](https://doi.org/10.2147/CMAR.S173511)
 13. Vaira LA, Hopkins C, Sandison A, et al.: Olfactory epithelium histopathological findings in long-term coronavirus disease 2019 related anosmia. *J Laryngol Otol.* 2020, 134:1123-7. [10.1017/S0022215120002455](https://doi.org/10.1017/S0022215120002455)
 14. Brann DH, Tsukahara T, Weinreb C, et al.: Non-neuronal expression of SARS-CoV-2 entry genes in the olfactory system suggests mechanisms underlying COVID-19-associated anosmia. *Sci Adv.* 2020, 6:1-5. [10.1126/sciadv.abc5801](https://doi.org/10.1126/sciadv.abc5801)
 15. Barizien N, Le Guen M, Russel S, Touche P, Huang F, Vallée A: Clinical characterization of dysautonomia in long COVID-19 patients. *Sci Rep.* 2021, 11:14042. [10.1038/s41598-021-93546-5](https://doi.org/10.1038/s41598-021-93546-5)
 16. Gupta K, Mohanty SK, Mittal A, et al.: The cellular basis of loss of smell in 2019-nCoV-infected individuals. *Brief Bioinform.* 2021, 22:873-81. [10.1093/bib/bbaa168](https://doi.org/10.1093/bib/bbaa168)
 17. Ruiz-Ortega M, Lorenzo O, Suzuki Y, Rupérez M, Egido J: Proinflammatory actions of angiotensins. *Curr Opin Nephrol Hypertens.* 2001, 10:321-9. [10.1097/00041552-200105000-00005](https://doi.org/10.1097/00041552-200105000-00005)
 18. Verma S, Abbas M, Verma S, et al.: Impact of I/D polymorphism of angiotensin-converting enzyme 1 (ACE1) gene on the severity of COVID-19 patients. *Infect Genet Evol.* 2021, 91:104801. [10.1016/j.meegid.2021.104801](https://doi.org/10.1016/j.meegid.2021.104801)
 19. Fujii H, Tsuji T, Yuba T, et al.: High levels of anti-SSA/Ro antibodies in COVID-19 patients with severe respiratory failure: a case-based review: high levels of anti-SSA/Ro antibodies in COVID-19. *Clin Rheumatol.* 2020, 39:3171-5. [10.1007/s10067-020-05359-y](https://doi.org/10.1007/s10067-020-05359-y)
 20. Zhang Y, Cao W, Jiang W, et al.: Profile of natural anticoagulant, coagulant factor and anti-phospholipid antibody in critically ill COVID-19 patients. *J Thromb Thrombolysis.* 2020, 50:580-6. [10.1007/s11239-020-02182-9](https://doi.org/10.1007/s11239-020-02182-9)
 21. Wang EY, Mao T, Klein J, et al.: Diverse functional autoantibodies in patients with COVID-19. *Nature.* 2021, 595:283-8. [10.1038/s41586-021-03631-y](https://doi.org/10.1038/s41586-021-03631-y)
 22. Gourtsoyannis Y: COVID-19: possible reasons for the increased prevalence of olfactory and gustatory dysfunction observed in European studies. *Clin Infect Dis.* 2020, 71:c1aa685. [10.1093/cid/ciaa685](https://doi.org/10.1093/cid/ciaa685)
 23. Somekh I, Yakub Hanna H, Heller E, Bibi H, Somekh E: Age-dependent sensory impairment in COVID-19 infection and its correlation with ACE2 expression. *Pediatr Infect Dis J.* 2020, 59:e270-2. [10.1097/INF.0000000000002817](https://doi.org/10.1097/INF.0000000000002817)
 24. Lechien JR, Chiesa-Estomba CM, De Siati DR, et al.: Olfactory and gustatory dysfunctions as a clinical presentation of mild-to-moderate forms of the coronavirus disease (COVID-19): a multicenter European study. *Eur Arch Otorhinolaryngol.* 2020, 277:2251-61. [10.1007/s00405-020-05965-1](https://doi.org/10.1007/s00405-020-05965-1)
 25. Dani M, Dirksen A, Taraborrelli P, Torocastro M, Panagopoulos D, Sutton R, Lim PB: Autonomic dysfunction in 'long COVID': rationale, physiology and management strategies. *Clin Med (Lond).* 2021, 21:e63-7. [10.7861/clinmed.2020-0896](https://doi.org/10.7861/clinmed.2020-0896)
 26. van Campen CL, Rowe PC, Visser FC: Cerebral blood flow remains reduced after tilt testing in myalgic encephalomyelitis/chronic fatigue syndrome patients. *Clin Neurophysiol Pract.* 2021, 6:245-55. [10.1016/j.cnp.2021.09.001](https://doi.org/10.1016/j.cnp.2021.09.001)
 27. ter Laan M, van Dijk JM, Elting JW, Staal MJ, Absalom AR: Sympathetic regulation of cerebral blood flow in humans: a review. *Br J Anaesth.* 2013, 111:361-7. [10.1093/bja/aet122](https://doi.org/10.1093/bja/aet122)